



EVALUATION OF EFFECTIVENESS OF MYRRH GUM EXTRACT ON SOME BIOCHEMICAL AND HISTOLOGICAL PARAMETERS IN MALE RATS INDUCED CHRONIC RENAL FAILURE (CRF)

Ahmed Neema AL-Mosawy* and Saatar Jasim Hatroosh

Department of Biology, College of Education for Pure Science, University of Karbala, Iraq

*Author for correspondence: almosawy748@gmail.com

Abstract

The objective of the study was to test water extract of *Commiphora molmol* by trying to treat chronic renal failure that induced by Cadmium chloride CdCl₂, at a concentration of 5 mg /kg body. wt./day of on rat at chronic level with drinking water for six weeks as animal model. Cadmium chloride CdCl₂, at a concentration of 5 mg /kg body. wt./day of on rat at chronic level with drinking water for six weeks as animal model. measuring some predicate biomarkers and histopathological sections functional common kidney biomarker was done serum creatinine and novel biomarker measured kidney injury molecule-1(KIM-1) and Neutrophils associated gelatinase lipocalin(NGAL), Cystatin C, also histopathological sections done for Hematoxylin & Eosin, Our findings demonstrate that a regular oral intake of CdCl₂ solution (in drinking water) for 45 days causes severe damage to rat kidneys and after treatment with extract of *C. molmol* lead to relatively normal rat kidneys. There is significant increase of Serum Urea, creatinine, KIM-1, NGAL and Cystatin C, when compared with control group, also indicate there is significant increase in serum biomarkers for kidney injury. After the treatment with water extract of *C. molmol* by different concentrations 10, 20, and 30 mg/kg all these Urea, Scr., KIM-1, NGAL and Cystatin C were significantly decrease when compared with CdCl₂ group, compared with control group and after the treatment the damages were not found or minimize. At this exposure of CdCl₂, cortex region is most affected whereas glomeruli as well as proximal tubules showed wall thickening. Cytosolic damaged bodies were also observed in the renal tubular epithelium. The biomarkers KIM-1 and NGAL may be good predictive indicator of chronic renal failure, plant extract may be having a highly effect for treating the renal failure and this was shown through the sections of the tissue in addition to biomarkers tests which reveal the induced chronic renal failure groups showed highly response to treatment.

Keywords: induced renal failure, kidney injury molecule-1, Neutrophils associated gelatinase

Introduction

Kidneys are dynamic organs and represent the major control system maintaining the body hemostasis; they are affected by many chemicals and drugs that may affect their function (Maliakel *et al.*, 2008). Changes in renal function are one of the most common manifestations of severe illness. Their importance is reflected in the routine physiological and biochemical monitoring of kidney function via urine output measures and blood laboratory measurement in critically ill patients (Hawkins, 2011). Chronic kidney disease is associated with high morbidity and mortality (Wenet *et al.*, 2014). The kidney contains many xenobiotic metabolizing enzymes and plays a central role in metabolizing drugs and foreign compounds in the body. Kidney diseases represent a public health issue worldwide and can range from mild infection to dangerous kidney failure (Nasri, 2009). Renal failure (RF) a state of kidney in which fails for removing and concentrating metabolic end products from the blood, regulating the fluid, electrolytes, and regulation the pH in the extracellular fluids. There are different causes may lead to kidney disease, systemic disease, and/or urologic defects not related with kidney (Kasper *et al.*, 2005). The kidney has important and the main role in excretion of many chemicals and drugs. So, the renal failure may lead to reservation, of these compounds, which may accumulate gradually to toxic levels (Ferguson *et al.*, 2008). Whereas some models of renal failure animal are used to evaluate the damage of organs pathogenesis (Bellomo *et al.*, 2004). Different studies persist to discover new biomarkers that are identification the kidney disease, and understanding the intensity and development of renal failure when examination noninvasively in urine and blood. The biomarker includes Cystatin C, kidney injury molecule 1 (KIM-1), Neutrophil gelatinase-associated lipocalin (NGAL) (Devarjan, 2011). KIM-1 is a type I

transmembrane glycoprotein which is not found in normal kidneys. The elevation in releasing of this protein was found at highly levels on the proximal tubule cells specially on the apical membrane after nephrotoxic or ischemic injury, and in rats it is widely induced in the tubules after ischemic or toxic injury (Guo *et al.*, 2012; Ichimura *et al.*, 2004). KIM-1 is released into the circulation where kidney injury in rodents and humans with CRF (Sabbisett *et al.*, 2014). Neutrophil gelatinase associated lipocalin (NGAL) is a small protein (25kDa) that related to the family of lipocalin protein, is produced in epithelial cells and neutrophils in most tissues, it is a marker of tubular injury of kidney (Cowland *et al.*, 2003) also, NGAL, called lipocalin-2 osteopontin (bone phosphoprotein), located in activated neutrophils, a coordinate with its function as an innate antibacterial factor by interfering with bacterial iron uptake (Zhao, 2010). NGAL may eventually have important role in predicting both acute and chronic renal failure (Bolognino *et al.*, 2008).

Cystatin C is a 13 kDa cysteine protease inhibitor that is produced by cells throughout the body. Cystatin C is abundant in serum/plasma and is readily filtered at the glomerulus. Serum levels of cystatin C have been proposed as a useful marker to estimate glomerular filtration rate (Peralta *et al.*, 2011). Unlike creatinine, cystatin C is not secreted by the proximal tubule. Instead, filtered cystatin C is taken up through a megalin-dependent process and then completely catabolized in proximal tubule epithelial cells (Ghys *et al.*, 2014). Serum levels of cystatin C are much less likely to be affected by factors such as gender, metabolic status or disease states than are levels of creatinine (Ghys *et al.*, 2014; Parikh *et al.*, 2011). Cystatin C has recently received some attention as a potential biomarker of Cd nephrotoxicity (Harisa *et al.*, 2014; Poreba *et al.*, 2011; Wallin *et al.*, 2014). Those studies focused primarily on the

measurement of serum levels of cystatin C as an indicator of glomerular function and they yielded equivocal and somewhat conflicting results. Most of the studies did not include data on the possible effects of Cd on the urinary excretion of cystatin C. Medicinal plants and their derived bioactive phytochemicals have been gaining recognition in the treatment of neurological diseases. *C. molmol* (Myrrh) {family *Burseraceae*} is a shrub resembling tropical tree grows in dry forest and produces a resinous exudate called myrrh or oleo-gum resin (Hanus *et al.*, 2005). Myrrh has been used traditionally for several centuries for the treatment of various diseases and has showed multiple beneficial effects, including antibacterial (Rahman *et al.*, 2008), hypoglycemic (Salama *et al.*, 2014), anti-inflammatory, antioxidant (Ashry *et al.*, 2010).

Materials and Methods

Al-Myrrh gum was obtained from Al-Razi Center for Alternative Medicine, Baghdad, Iraq the gum plant was identified by the National Herb in Abu Ghraib, Baghdad. The gum powder was moistened with 1: 5 water (50 g of powder was mixed with 250 ml of distilled water), (Harborne, 1984). A horizontal shaker was used for 30 minutes, the sample was left stationary, then filtered using filter paper 3 times. Centrifuge (3000 rpm) was then used for 15 minutes. Concentrate the extract using rotary evaporator, and dry at 45 °C in the oven. The water extract was used in the study of animals.

Experimental design and treatments: Thirty adult male *Rattus norvegicus* weighing 200-240 g were used in the present study. The animals were obtained from the animal house in the biology department of College science of Thiqar University and were housed in well-aerated cages at normal atmospheric temperature and normal 12-hour light/dark cycle. The animals had free access to water and a standard diet of known composition. All efforts were done to reduce the number and suffering of animals and all animal procedures were in accordance with the recommendations of the animal ethics committee of Karbala University). The experimental animals were divided into five groups as follows:

Group I negative control group (C): The normal drinking water was given for the duration of the experiment (15 animals) 5 animals for the first week 5 animals for the second week 5 animals for the third week.

Group II positive control group: Induced renal failure by cadmium chloride (15 animals) 5 animals per week.

Group III Treatment group first (T1): group of animals induced renal failure and treated with a water extract of gum myrrh 10 mg / kg body weight and the number of 5 animals per week

Group IV Treatment group Second (T2): group of animals induced renal failure and treated with a water extract of gum myrrh 20 mg / kg body weight and the number of 5 animals per week.

Group V Treatment group third (T3): group of animals induced renal failure and treated with a water extract of gum myrrh 30 mg / kg body weight and the number of 5 animals per week. At the end of the experiment, rats were sacrificed

under mild anesthesia and blood samples were obtained for serum preparation. Kidneys were rapidly excised and immediately perfused with ice-cold saline. Samples from the kidney were homogenized in cold phosphate buffered saline (10% w/v), centrifuged and clear homogenate was separated and stored at -20°C. studies parameter was measured according to the instruction of the Elabscience company by using ELIZA. **Histology:** Kidney samples fixed in 10% neutral buffered formalin were dehydrated in ascending ethanol series, cleared in xylene, and embedded in paraffin wax. Blocks were prepared, and 4- μ m thick sections were cut by a sledge microtome. The paraffin embedded sections were deparaffinized, washed, and stained with hematoxylin and eosin (H&E) for histopathological examination under light microscope. To demonstrate collagen deposition in the kidney, paraffin sections.

Statistical Analysis

Statistical analysis was performed using SPSS (v.25). Results were expressed as mean \pm standard deviation (SD) and all statistical comparisons were made by means of the one-way analysis of variance (ANOVA) test followed by Tukey's test post hoc analysis. (P value less than 0.05 was considered significant).

Results

Serum Urea & Creatinine levels for male rat

The results of the development of experimental chronic renal failure in laboratory animals by cadmium chloride CdCl₂, shown in Table (1) &(2), show that serum urea & creatinine levels in male rats in the form of mean \pm SD mean, Had a significant difference at a probability level of $P \leq 0.05$ in the cadmium chloride dosage group compared to the control group. It was found that the treatment of animals induced in chronic renal failure with the water extract of a bitter gum and the dose of 10, 20, and 30 mg / kg and at a rate of once a day for (first, second and third week) at a value of $P \leq 0.05$ levels of serum Urea & Creatinine compared to the cadmium chloride group, but the level of decline did not reach the level in the control group. It was also shown from the table that the dosage period had an effect on serum Urea & Creatinine levels for male rats. The difference was statistically significant at $P \leq 0.05$ after (first, second, and third week) of the dosage of water extract of myrrh gum after six weeks of chronic renal failure.

Serum levels of KIM-1, NAGL, and Cystatin C for male rat

Table 3,4,5 showed that the development of experimental chronic renal failure in experimental animals led to an increase in serum of KIM-1, NAGL, and Cystatin C levels respectively, in the treated group with cadmium chloride compared to the control group. It was found that treatment of chronic renal failure patients with water extract of myrrh gum and dose 10, 20, ($P < 0.05$) at KIM-1, NAGL, and Cystatin C levels compared with the control group, showed a significant effect ($P < 0.05$) on KIM-1, NAGL, and Cystatin C levels in the serum of male rats where the decrease was significant ($P < 0.05$) after (first week, second and third) of the dosage of the water extract of the gum compared with six weeks after Chronic renal failure.

Table 1 : Effect of water extract of *C. molmol* on the level of Urea mg/dl in male rats' serum compared to control Mean± Standard deviation

Time		Groups	Mean± S.D.					
			Control	CdCl ₂	10mg/kg	20mg/kg	30mg/kg	LSD groups
Commiphora molmol	First week		23.08±3.05	97.51±1.73	62.36±2.53	57.16±3.62	41.16±1.64	3.26
	Second week		26.56±0.88	95.54±2.02	62.29±4.34	56.62±1.58	38.20±1.14	2.9
	Third week		22.10±0.63	96.65±1.84	62.08±2.77	51.91±4.27	38.27±1.03	3.07
	Mean of time		23.91±2.63	96.57±1.92	62.24±3.07	55.23±3.95	39.21±1.87	
	LSD time		2.31	2.31	4.1	4.16	1.61	
	LSD extraction		0.53					

Table 2 : Effect of water extract of *C. molmol* on the level of Creatinine mg/dl in male rats' serum compared to control Mean± Standard deviation

Time		Groups	Mean± S.D.					
			Control	CdCl ₂	10mg/kg	20mg/kg	30mg/kg	LSD groups
Commiphora molmol	First week		0.70±0.13	3.82±0.41	3.26±0.39	2.84±0.54	2.64±0.31	0.47
	Second week		0.71±0.10	3.89±0.55	3.01±0.49	2.29±0.46	2.18±0.31	0.51
	Third week		0.73±0.10	4.13±0.19	2.69±0.59	2.25±0.42	1.88±0.39	0.47
	Mean of time		0.71±0.10	3.94±0.40	2.99±0.52	2.46±0.52	2.23±0.45	
	LSD time		0.14	0.51	0.62	0.59	0.42	
	LSD extraction		0.45					

Table 3 : Effect of water extract of *C. molmol* on the level of KIM-1 pg / ml in male rats' serum compared to control Mean± Standard deviation

Time		Groups	Mean± S.D.					
			Control	CdCl ₂	10mg/kg	20mg/kg	30mg/kg	LSD groups
Commiphora molmol	First week		113.60±10.24	806.20±51.84	407.60±55.27	341.60±105.37	304.20±28.47	73.88
	Second week		111.40±7.30	808.40±74.77	390.40±78.02	324.00±41.85	276.80±35.93	67.8
	Third week		108.80±5.17	812.80±23.32	315.60±52.26	267.40±74.24	247.80±23.13	53.6
	Mean of time		111.27±7.54	809.13±50.28	371.20±71.42	311.00±79.51	276.27±36.35	
	LSD time		9.73	67.22	77.99	96.99	36.75	
	LSD extraction		0.87					

Table 4 : Effect of water extract of *C. molmol* on the level of NAGL pg / ml in male rats' serum compared to control Mean± Standard deviation

Time		Groups	Mean± S.D.					
			Control	CdCl ₂	10mg/kg	20mg/kg	30mg/kg	LSD groups
Commiphora molmol	First week		1100.6±180.4	1964.7±98.8	1406.6±131.3	1207.0±37.6	1190.6±56.4	140.37
	Second week		1039.9±110.8	1984.6±69.4	1375.7±114.9	1188.1±67.9	1178.1±66.5	109.95
	Third week		1026.4±117.0	2046.6±134.7	1327.5±73.1	1176.8±49.6	1185.4±49.8	113.79
	Mean of time		1055.6±133.5	1998.7±103.2	1370.0±106.6	1190.6±144.6	1184.7±53.9	
	LSD time		173.12	129.48	135.38	65.93	71.85	
	LSD extraction		0.99					

Table 5 : Effect of water extract of *C. molmol* on the level of Cystatin C pg / ml in male rats' serum compared to control Mean± Standard deviation

Time		Groups	Mean± S.D.					
			Control	CdCl ₂	10mg/kg	20mg/kg	30mg/kg	LSD groups
Commiphora molmol	First week		87.44±8.26	195.34±14.22	152.09±17.25	141.85±10.09	141.30±11.51	15.7
	Second week		89.77±10.36	193.52±12.19	144.30±6.22	137.80±16.01	139.78±20.12	17.14
	Third week		91.30±8.22	201.64±11.65	135.31±7.24	140.52±11.74	138.53±10.89	12.54
	Mean of time		89.50±8.49	196.83±12.33	143.90±12.71	140.06±12.03	139.87±13.74	
	LSD time		11.16	15.79	14.11	15.94	18.32	
	LSD extraction		0.82					

Histopathological study

The results of the histological examination in the current study in Figure (1) showed a cross-sectional tissue of the white rat male control group. There are a number of normal nephrons containing a malbigic pelvis consisting of the Bowman and the glomerular sac. In the cross section of the kidney, the proximal and distant urinary tubules were

marked with cubic epithelial cells. The histopathological sections of the current study in Figure (2) of the cadmium chloride group showed that the glomerular glands in the cortex are dilated with occasional atrophy, some of which have severe vulvar thickness, Bowman space expansion, and more severe degeneration of the epithelial cells of renal tubules and even necrosis, as well as the necrosis to the

cavity and the area of the pulp was normal as well as observed inflammatory cell infiltration compared to the control group.

The results of the histological examination in the current study in Figure (3) were transversally transcribed to the kidney of the white rat males treated with cadmium chloride after treatment with the water extract of the *C. molmol* at 10 mg / kg concentration. The renal glands in the cortex are normal and there is no inflammation. As well as in most degenerative changes in the renal tubes and lack of congestion in the blood vessels. Average necrosis was observed in the cells of the renal tubules compared to the infected group. The results of the histological examination in the current study showed (4) a transverse tissue section of the male white rat kidney of the cadmium chloride group after treatment with the water extract of the *C. molmol* powder at a concentration of (20 mg / kg). The renal glands in the cortex are normal and the absence of inflammation and absence of changes Degeneration of the renal tubes, presence of congestion in the blood vessels and presence of necrosis in the cells of the walls of renal tubules compared to the infected group. The results of the histological examination in the current study showed (5) a transverse tissue section of the male white rat kidney of the cadmium chloride group after treatment with the water extract of the *C. molmol* at 30 mg / kg concentration. The renal glands in the cortex are normal and there is no inflammation and no changes Axial degeneration of the renal tubules and absence of moderate congestion in the blood vessels. The presence of protein substances is relatively normal in the enlarged renal tubules compared to the infected group.

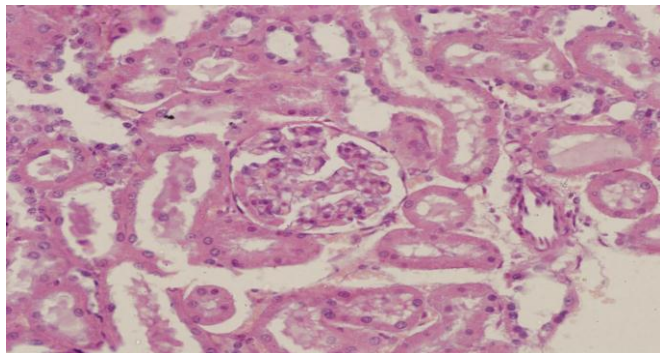


Fig. 1 : A section of the kidney tissue of an uninfected rat. Natural glomeruli are shown as normal urinary tubules lined with cubic epithelial cells (400X) H & E.

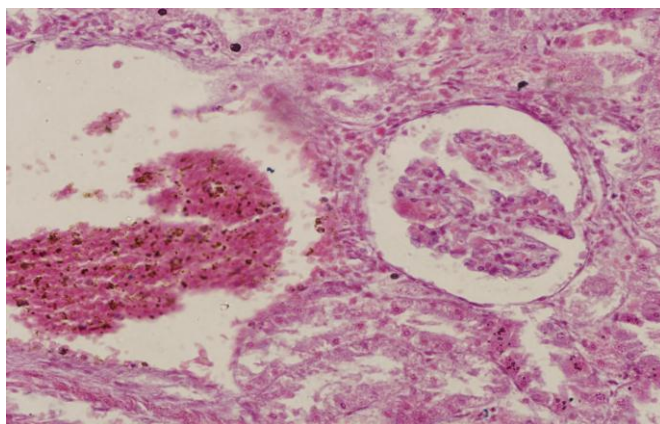


Fig. 2 : A segment of the kidney tissue of a rat with chronic renal failure by cadmium chloride three weeks after injury (400X) H & E necrosis congestion shrinkage glomerular

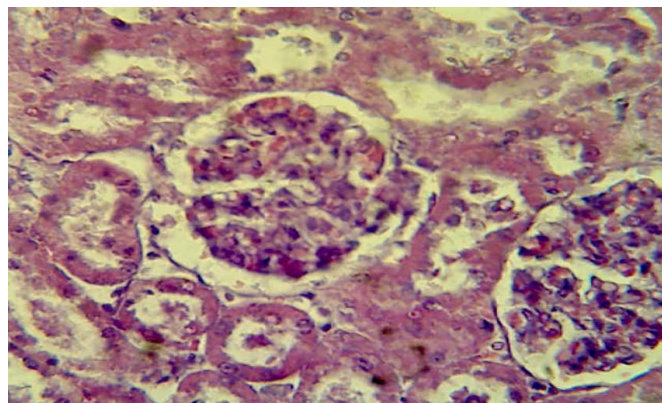


Fig. 3 : A segment of the kidney tissue of a rat with chronic renal failure by cadmium chloride after treatment with 10 mg / kg of water extract *C. molmol* (400X) H & E} mild necrosis mild degeneration and no significant congestion and inflammation.

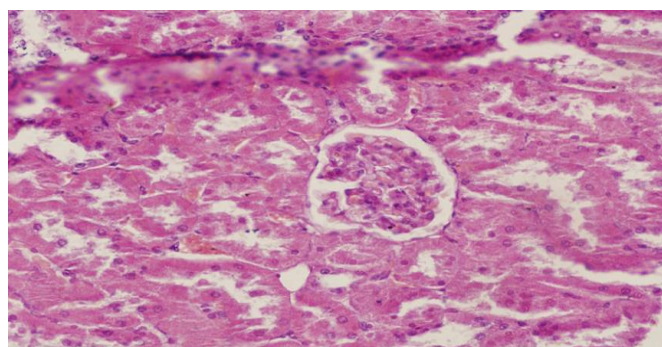


Fig. 4 : A section of the kidney tissue of a rat with chronic renal failure by cadmium chloride after treatment with 20 mg / kg of water extract *C. molmol*. (H & E) necrosis congestion

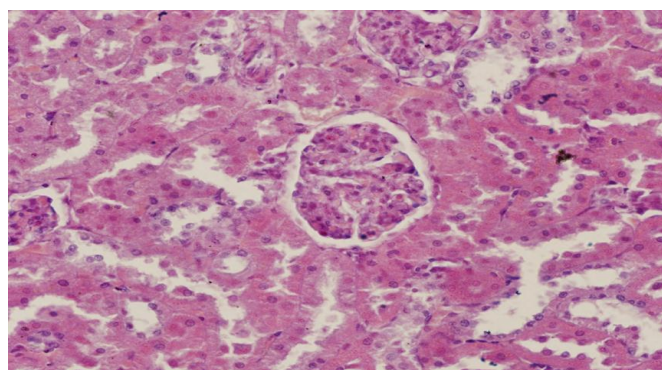


Fig. 5 : A fragment of the kidney tissue of a rat with chronic renal failure by cadmium chloride after treatment with 30 mg / kg of water extract *C. molmol*. H & E relatively normal secretion, no inflammation, No significant congestion inflammation.

Discussion

Urea assessment in rats' groups of induced chronic renal failure; Cdcl2, Control, treated with water extract at doses 10, 20 and 30 mg/kg.

Several studies have been conducted on the physiological and histological effects of cadmium on humans (Ortega *et al.*, 1998) and on laboratory animals (Shaik *et al.*, 1999; Pourahmed and Obrien, 2000). Our current findings indicate that exposure to cadmium chloride has led to kidney failure, which is the significant increase in creatinine and urea concentration in the groups treated with cadmium chloride in the first and second weeks compared to control

groups. These results are consistent with the data obtained by (Moawad and Adel-Dayem, 1998; Mohamed, 2011; Marek *et al.*, 2013; Ibrahim, 2014). High levels of Urea may cause dysfunction of epithelial cells in the nucleus and the weakness of proximal function (Gowda and Ledoux, 2008). Treatment of groups treated with cadmium chloride in Arabic AG significantly decreased the levels of urea and creatinine elevated to be within control levels. The levels of urea in circulation were significantly increased ($P < 0.001$) in mice induced by methotrexate MTX compared to the control group. Pre-treatment of MTX-induced mice for 15 days using *C. molmol* extract yielded significant improvement in serum urea levels (Mahmoud *et al.*, 2018). These results were consistent with several studies showing the antioxidant potential of *C. molmol* resin. In rodent models of hypercalcemia (Mahmoud *et al.*, 2017).

Creatinine assessment in rats' groups of induced chronic renal failure; CdCl₂, Control, treated with water extract at doses 10, 20 and 30 mg/kg.

Our current findings indicate that exposure to cadmium chloride has led to kidney failure, which is the significant increase in Creatinine and Urea concentration in the groups treated with cadmium chloride in the first and second weeks compared to control groups. These results are consistent with the data obtained by (Moawad and Adel-Dayem, 1998; Mohamed, 2011).

Creatinine concentration shown significantly elevated in adenine group by comparison with the control group, this our data agrees with (Imarh, 2017; Aqutub, 2019) in rat, that found, significant increase in serum creatinine and urea concentration by comparison with control group. If the level of the urea and creatinine become higher, this may refer to impairment of epithelial cells transportation ability, in collecting tubules and wide disturbances in the function of proximal tubules (Gowda and Ledoux, 2008). Previous study has shown that the changes in levels of creatinine and urea in blood, may occur as a result to the necrosis of renal parenchyma (Fung and Clark, 2004).

Kidney injury molecule -1 concentration in serum of male rats induced chronic renal failure treated with the water extract 10,20 and 30 mg/kg.

Concentration of KIM-1 in cadmium chloride group statistically increased when compared with control group as showed in table (3).

The current study agrees with the study conducted by (Aguar *et al.*, 2015) who found elevation of KIM-1 concentration in induced CRF, also present study agrees with study done by and (Park *et al.*, 2013; Imarh, 2017; Aqutub, 2019) were found increase KIM-1 concentration in cases with CRF by comparison with control group.

Whereas increase KIM-1 concentration indicate to any damage to the kidney due to it one of the compounds of the tubular epithelial cells and any causes such as oxidative stress lead to damage these cells and loss there content to interstitial tissue then leak to the circulation there for KIM -1 may be is considered a biomarker for diagnosis kidney damage, oil extract of *Eruca sativa* have antioxidant effect therefore lead to repair the damage and protect the cells against oxidative stress which lead to decrease in KIM-1 release, finally decrease KIM-1 concentration in circulation,

(Park *et al.*, 2013) who refer to antioxidant activity that resemble present study.

Neutrophil associated gelatinase lipocalin concentration in serum of male rats induced chronic renal failure treated with the water extract 10, 20 and 30 mg/kg.

Whereas NGAL is highly expressed protein in ischemic or renal injury that related to toxin in experimental models (Mishra *et al.*, 2004) and in humans (Mishra *et al.*, 2005; Mitsnefes *et al.*, 2007) show that NGAL concentration in serum it is considered as a sensitive and specific biomarker for diagnosis and a novel biomarker of CKD. Therefore, the activity of endogenous antioxidant enzymes, oxidative stress in plasma and renal tissue, and urinary excretion of tubular proteins as candidate of early biomarkers of tubular injury (Arellano-Buendo *et al.*, 2014).

Cystatin C concentration in serum of male rats induced chronic renal failure treated with the water extract 10, 20 and 30 mg/kg.

Cystatin C is an emerging marker of both ischemic and nephrotoxic kidney injury (Ghys *et al.*, 2014). Serum levels of cystatin C have been proposed as an alternative to traditional markers such as BUN and creatinine for the estimation of glomerular filtration rate (Ghys *et al.*, 2014). At the same time, increases in the urinary excretion of cystatin C have been proposed as a sensitive indicator of proximal tubular injury (Ghys *et al.*, 2014; Wallin *et al.*, 2014). The fact that cystatin C is rapidly being accepted as a measure of renal function in the clinic makes it extremely important to understand the effects that specific nephrotoxic agents, such as Cd, have on serum and urinary levels of cystatin C.

Histopathological changes of induced CRF

The results of the current study showed that the treatment of cadmium chloride for white rat males has led to changes in the tissues of the kidneys of these animals compared with the control group. The cause of these changes in the kidney tissue is due to the arrival of cadmium to the kidney through the bloodstream because the kidney is the target organ. The second of the toxicity of these elements because it is the important member in the elimination of the body of toxic substances because these elements cause significant damage in the kidney, whether in the cortex and Bowman Governor has caused cadmium damage other than bloody hemorrhage and purulent swelling of epithelial lining of the renal tubules and within the cavity, and the infiltration of inflammatory cells and these are consistent with the policies included him (AL-obeidi, 2008; Abdul Shujayri, 2016).

The current study showed that the most affected areas of the kidney are the crust and glomeruli, which appear to be empty, clotted, and shrunken, and that the first kidney failure occurs in the renal tubules near the crust (AL-obeidi, 2008; Bull, 2000) causing cadmium damage renal tubules, which causes different degrees of renal inflammation and thus affects the rate of renal absorption with tissue changes in the endothelial cells of the renal tubules. Cell cells also oxidize cellular membranes, damaging their membranes and destroying them (AL-obeidi, 2008). Effect of Myrrh on liver and kidney toxicity caused by CCl₄ administration of mice. Radical tissue substitutions were recorded in renal and liver tissues such as the appearance of necrotic regions, cellular infiltration, renal tubular atrophy, renal tubular endothelial

reaction with renal cavity expansion and eosinophilic appearance. Treatment using Myrrh showed small formal anomalies in some measured parameters compared with control mice. The current results are consistent with many experimental and pre-clinical studies on the Myrrh extract, which have demonstrated their safety in use (Salama *et al.*, 2014).

Conclusion

From current study conclude that the biomarkers Urea, Creatinine, KIM-1, NAGL and Cystatin C may be good predictive indicator of renal failure, plant extract may be has a highly effect for treating the renal failure and this was shown through the sections of the tissue in addition to biomarkers tests which reveal the induced CRF groups showed high response to treatment.

References

- Abdul, S. and Ayat, H.A. (2016). Effect of water extract of black raisins (*Vitis vinifera* L.) on some physiological and histological parameters of white rat males treated with cadmium chloride. Master Thesis. Faculty of Education, Karbala University.
- Aguiar, C.F.; Naffah-de-Souza, C.; Castoldi, A.; Corrêa-Costa, M.; Tarcio Braga, T.; Naka, É.L.; Amano, M.T.; Débora, T.R.S.; Abate, Hiyane, M.I.; Cenedeze, M.A.; Pacheco, A.; Filho, S. and Câmara, N.O.S. (2015). Administration of α -Galactosylceramide Improves Adenine-Induced Renal Injury; *Mol. Med.*, 21: 553-562.
- Al-Obeidi, S.H.K. (2008). The effect of cadmium and lithium chloride in some blood parameters and biomarkers of male New Zealand rabbits. Master Thesis. Faculty of Education, Karbala University.
- AL-Qutub A.H. (2019). Evaluate some coagulation factors in rats with induced- chronic renal failure and possible protective role of tomato powder. MSc. Thesis University of Karbala College of Veterinary Medicine.
- Arellano-Buendía, A.S.; García-Arroyo, F.E.; Cristóbal-García, M.; Loredó-Mendoza, M.L.; Tapia-Rodríguez, E.; Sánchez-Lozada, L.G. and Osorio-Alonso, H. (2014). Urinary Excretion of Neutrophil Gelatinase-Associated Lipocalin in Diabetic Rats; *Oxidative Medicine and Cellular Longevity*, Pages 11.
- Ashry, K.M.; El-Sayed, Y.S.; Khamiss, R.M. and El-Ashmawy, I.M. (2010). Oxidative stress and immunotoxic effects of lead and their amelioration with myrrh (*Commiphora molmol*) emulsion, *Food and Chemical Toxicology*, 48(1): 236–241.
- Ayman, M.M.; Mousa, O.; Germoushd, Khalid M. Al-Anazie, Ahmed H. Mahmoud, Mohammad Abul Farahe, Ahmed A. (2018). Allamf *Commiphora molmol* protects against methotrexate-induced nephrotoxicity by up-regulating Nrf2/ARE/HO-1 signaling.
- Bellomo, R.; Ronco, C.; Kellum, J.; Mehta, R. and Palevsky, P. (2004). The ADQI workgroup. Acute renal failure – definition, outcome measures, animal models, fluid therapy and information technology needs: The Second International Consensus Conference of the Acute Dialysis Quality Initiative (ADQI) Group. *Critical Care* 8: R204–12.
- Bolignano, D.; Donato, V.; Coppolino, G.; Campo, S.; Buemi, A.; Lacquaniti, A. and Buemi, M. (2008). Neutrophil gelatinase-associated lipocalin (NGAL) as a marker of kidney damage. *Am J Kidney Dis*; 52: 595-605.
- Bull, W. (2000). Cadmium – induced changes in hematology and 2,3 DPG levels in rat. *Environ. Contamin. Toxicol.*, 64: 93-99.
- Cowland, J.B.; Sorensen, O.E. and Sehested, M. (2003). Neutrophil gelatinase-associated lipocalin is up-regulated in human epithelial cells by IL-1 beta, but not by TNF-alpha. *J Immunol.* 171: 6630–6639.
- Devarajan, P. (2011). The Use of Targeted Biomarkers for Chronic Kidney Disease. *Adv. Chronic Kidney Dis.*, 17(6): 469-479.
- Ferguson, M.A.; Vaidya, V.S. and Bonventre, J.V. (2008). Biomarkers of nephrotoxic acute kidney injury. *Toxicology*, 245: 182-193.
- Fung, F. and Clark, R.F. (2004). Health effects of mycotoxins: a toxicological overview. *J. Toxicol. Clin. Toxicol.*, 42: 217–234.
- Ghys, L.; Paepe, D.; Smets, P.; Lefebvre, H.; Delanghe, J. and Daminet, S. (2014). Cystatin C: a new renal marker and its potential use in small animal medicine. *J Vet Intern Med*, 28: 1152–1164.
- Gowda, N.K.S. and Ledoux, D.R. (2008). Use of antioxidants in amelioration of mycotoxin toxicity: a review. *Anim. Nutr. Feed. Technol.* 8: 1–11.
- Guo, L.; Takino, T.; Endo, Y.; Domoto, T. and Sato, H. (2012). Shedding of kidney injury molecule-1 by membrane-type 1 matrix metalloproteinase. *J Biochem*, 152: 425-432.
- Hanus, L.O.; Rezanka, T.; Dembitsky, V.M. and Moussaieff, A. (2005). Myrrh-Commiphora chemistry, *Biomedical Papers of the Medical Faculty of the University Palacky, Olomouc, Czech Republic*, 149(1): 3–27.
- Harborne, J.B. (1984). *Physicochemical Methods, a guide to modern techniques of plant analysis*, 2nd Ed. Chapman and Hall. London, New York. 288p.
- Harisa, G.I.; Attia, S.M.; Ashour, A.E.; Abdallah, G.M.; Omran, G.A. and Touliabah, H.E. (2014). Cigarette smoking and hyperglycemia increase renal response to low levels of cadmium in welders: cystatin C as a sensitive marker. *Biol Trace Elem Res.*, 158: 289–296.
- Hawkins, R. (2011). New biomarkers of acute kidney injury and the cardio-renal syndrome. *Korean J Lab Med.*, 31: 72-80.
- Ibrahim, M.A. (2014). Assessment of the therapeutic role of Arabic Gum as Antioxidants on Cadmium induced kidney dysfunction in male albino rats. *Inter. J. of Inn. and Sci. Res.*, 11(2): 322-329.
- Ichimura, T.; Hung, C.C.; Yang, S.A. *et al.* (2004). Kidney injury molecule-1: a tissue and urinary biomarker for nephrotoxicant induced renal injury. *Am J Physiol Renal Physiol*, 286: F552–F563.
- Imarah, A.A. (2017). Protective effect of *Eruca sativa* leaves oil extract against induced renal failure in rats according to certain physiological and histopathological criteria. A Thesis Submitted to the Council of the Faculty of Science University of Kufa.
- Kasper, D.L.; Fauci, A.S.; L-Longo, D.; Braunwald, E.; Hauser, S.L. and Jameson, J.L. (2005). *Harrisons' Principles of Internal Medicine*. 16th ed. Mc Graw-Hill, Medical Publishing Division. USA. 1639-1724.
- Mahmoud, A.M.; Alqahtani, S.; Othman, S.I.; Germoush, M.O.; Hussein, O.E.; Al-Basher, G.; Khim, J.S.; Al-Qaraawi, M.A.; Al-Harbi, H.M.; Fadel, A. and Allam,

- A.A. (2017) Commiphora molmol modulates glutamate-nitric oxide-cGMP and Nrf2/ARE/HO-1 pathways and attenuates oxidative stress and hematological alterations in hyperammonemic rats, *Oxid. Med. Cell. Longev.* 15: 7369671.
- Maliakel, D.M.; Kagiya, T.V. and Nair, C.K. (2008). Prevention of cisplatin-induced nephrotoxicity by glucosides of ascorbic acid and alphatocopherol. *Exp Toxicol Pathol*, 60(6): 521-527.
- Maret, W. and Moulis, Jean-Marc (2013). The Bioinorganic Chemistry of Cadmium in the Context of its Toxicity. In Astrid Sigel, Helmut Sigel and Roland K.O. Sigel. *Cadmium: From Toxicology to Essentiality. Metal Ions in Life Sciences* 11: 1–30.
- Mishra, J.; Dent, C. and Tarabishi, R. (2005). Neutrophil gelatinase associated lipocalin (NGAL) as a biomarker for acute renal injury after cardiac surgery; *The Lancet*, 365. 9466, pp. 1231–1238.
- Mishra, J.; Mori, K.; Ma, Q.; Kelly, C.; Barasch, J. and Devarajan, P. (2004). Neutrophil gelatinase-associated lipocalin: a novel early urinary biomarker for cisplatin nephrotoxicity; *Am. J. Nephrol.*, 24(3): 307–315.
- Mitsnefes, M.M.; Kathman, T.S.; Mishra, J. *et al.* (2007). Serum neutrophil gelatinase-associated lipocalin as a marker of renal function in children with chronic kidney disease, *Pediatric Nephrology*, 22(1): 101–108.
- Moawad, K.M. and Abdel-Dayem, S.M. (1998): Effect of royal jelly pretreatment on acute cadmium toxicity in male albino rats 2- kidney and bone. *Egypt. J. Histol.*, 21(10): 123-136.
- Mohamed, N.E. (2011). *J. American Science*, 7(6): 406-412.
- Nasri, H. (2009). World kidney day. Chronic kidney disease and aging: A global health alert. *Clin J Am Soc Nephrol*. 4: 1275-1283.
- Ortega, E.; Lorenzo, M.L.; Lopez, M.C. and Cabrera, C. (1998): Cadmium contamination of vegetable crops, farmlands and irrigation waters. *Rev. Environ. Contam. Toxicol.*, 154: 55 – 81.
- Parikh, C.R.; Coca, S.G.; Thiessen-Philbrook, H.; Shlipak, M.G.; Koyner, J.L.; Wang, Z.; Edelstein, C.L.; Devarajan, P.; Patel, U.D.; Zappitelli, M.; Krawczeski, C.D.; Passik, C.S.; Swaminathan, M. and Garg, A.X. (2011). Postoperative biomarkers predict acute kidney injury and poor outcomes after adult cardiac surgery. *J Am Soc Nephrol*, 22: 1748–1757.
- Park, S.; Kim, C.S.; Lee, J.; Suk, K.J. and Kim, J. (2013). Effect of regular exercise on the histochemical changes of d-galactose-induced oxidative renal injury in high-fat diet-fed rats. *Acta Histochem Cytochem*; 46(4): 111-119.
- Peralta, C.A.; Shlipak, M.G.; Judd, S.; Cushman, M.; McClellan, W.; Zakai, N.A.; Safford, M.M.; Zhang, X.; Muntner, P. and Warnock, D. (2011). Detection of chronic kidney disease with creatinine, cystatin C, and urine albumin-to-creatinine ratio and association with progression to end-stage renal disease and mortality. *JAMA* 305: 1545–1552.
- Poreba, R.; Gac, P.; Poreba, M.; Antonowicz-Juchniewicz, J. and Andrzejak, R. (2011). Relation between occupational exposure to lead, cadmium, arsenic and concentration of cystatin C. *Toxicolo.*, 283: 88–95.
- Pourahmed, J. and O'Brien, P. (2000). A comparison of hepatocyte cytotoxic mechanisms for Cu⁺² and Cd⁺². *Toxicolo.*, 143(3): 263 – 273.
- Rahman, M.M.; Garvey, M.L.; Piddock, J. and Gibbons, S. (2008). Antibacterial terpenes from the oleo-resin of *Commiphora molmol* (Engl.),” *Phytotherapy Research*, 22(10): 1356–1360.
- Sabbisetti, V.S.; Waikar, S.S.; Antoine, D.J.; Smiles, A.; Wang, C.; Ravisankar, A. *et al.* (2014). Blood kidney injury molecule-1 is a biomarker of acute and chronic kidney injury and predicts progression to ESRD in type I diabetes. *J Am Soc Nephrol*, 25: 2177-2186.
- Salama, A.; Ibrahim, W.; El-Nimr, T.; Abul-Rahman, M.A. and Tousson, E. (2014). Effect of myrrh extract (Mirazid®) on experimentally diabetic rats. *Pharmacologia*; 6: 135-142.
- Shaikh, Z.A.; Vu, T.T. and Zaman, K. (1999). Oxidative stress as a mechanism of chronic cadmium – induced hepatotoxicity and renal toxicity and protection by antioxidant. *Toxicol. Appl. Pharmacol.*, 154(3): 256 – 263.
- Wallin, M.; Sallsten, G.; Lundh, T. and Barregard, L. (2014). Low-level cadmium exposure and effects on kidney function. *Occup Environ Med.*, 71: 848–854.
- Wen, C.P.; Matsushita, K.; Coresh, J.; Iseki, K.; Islam, M.; Katz, R. *et al.* (2014). Relative risks of chronic kidney disease for mortality and endstage renal diseases across races are similar. *Kidney Int* doi: 10.1038/ki.2013.553.
- Zhao, C.; Ozaeta, P.; Fishpaugh, J.; Rupprecht, K.; Workman, R.; Grenier, F. and Ramsay, C. (2010). Structural characterization of glycoprotein ngal, an early predictive biomarker for acute kidney injury. *Carbohydr Res*; 345: 2252-2261.